

## CASE REPORT

# MALIGNANT PROLIFERATING TRICHILEMMAL TUMOR: A RARE NEOPLASM IN A RARER LOCATION. CASE REPORT AND REVIEW OF THE LITERATURE

Marco Montella<sup>1</sup>, Andrea Farabini<sup>2</sup>, Stefano Lucà<sup>1</sup>, Michele Donati<sup>3</sup>, Alfonso Baldi<sup>4,\*</sup>

<sup>1</sup> Pathology Unit, Department of Mental Health, Physic and Preventive Medicine, Luigi Vanvitelli University of Campania, Naples, Italy

<sup>2</sup> Istituto di Medicina e Scienza dello Sport Antonio Venerando, Rome, Italy

<sup>3</sup> Department of Pathology, University Hospital Campus Bio-Medico, Rome, Italy

<sup>4</sup> Department of Environmental, Biological and Pharmaceutical Sciences and Technologies, Luigi Vanvitelli, University of Campania, Caserta, Italy

\* Correspondence to: [✉ alfonsoaldi@tiscali.it](mailto:alfonsobaldi@tiscali.it), <https://orcid.org/0000-0002-8693-3842>.

**ABSTRACT:** Malignant proliferating trichilemmal tumor (MPTT) is an uncommon and malignant tumor of the skin, arising from the outer root sheath of the hair follicle. Most MPTTs occur in the head and neck area and affect the scalp predominantly. However, rarely, MPTT of other anatomical sites, such as back, buttocks, chest, elbow, vulva, mons pubis and nose, have been described. Although the malignant biological behaviour of the neoplasm, the known loco-regional aggression and the potential local and distant recurrences, surgical excision with free margins of normal tissue is generally curative and represents the gold standard of treatment. We describe a case of MPTT arising on the scrotum of 51-year-old man. Through this case and the review of the literature we try to establish the state of the art regarding the clinical aspects, the morphological and immunohistochemical features of this neoplasm. Finally, we underline the exceptionally rare location of the tumor in our case. To the best of our knowledge this is the first case of MPTT arising on scrotum.

**Doi:** 10.48286/aro.2022.55

**Impact statement:** Diagnosis and treatment of malignant trichilemmal tumor needs a multidisciplinary approach with a strong clinical-morphological correlation for an accurate diagnosis, particularly when it occurs in exceptionally rare sites.

**Key words:** *malignant trichilemmal tumor; trichilemmal malignant tumor; malignant proliferating trichilemmal tumor; proliferating trichilemmal carcinoma; MPTT.*

**Received:** September 13, 2022/**Accepted:** October 17, 2022/

**Published:** December 1, 2022

## INTRODUCTION

Malignant proliferating trichilemmal tumor (MPTT) is a rare, malignant skin tumor arising from the outer root sheath of the hair follicle (1). The term MPTT was originally employed by Saida *et al.* (2) in order to define skin neoplasms, diagnosed as Proliferating Trichilemmal Tumor (PTT), which showed malignant histological features as infiltrative growth pattern, nuclear atypia, high mitotic activity including atypical forms, and lymph node metastases (3). Even PTT is an uncommon skin tumor of the outer root sheath of the hair follicle with a benign but locally aggressive clinical behaviour (4). MPTT is considered to develop *de novo* or originate from a pre-existing

trichilemmal cyst (TC) or PTT, which is known as proliferating trichilemmal cyst (5, 6). Most MPTTs arise on the scalp but they were also observed on the back, buttocks, chest, elbow, vulva, mons pubis and nose (7). Clinically, the tumor occurs in both males and females, but affects women more frequently (8) and it appears as a dermic or subcutis nodule with an exophytic or ulcerated appearance and it varies in size, from less than 1 cm to more than 10 cm (9). Histologically, MPTT shows marked cytological atypia, cellular pleomorphism, atypical mitoses, dyskeratotic cells, and infiltrative growth pattern (1, 4, 10). The prognosis of MPTT is variable, including local

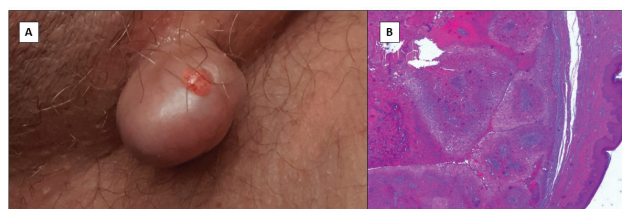
aggression, local and distant recurrence potential, mainly depending on the treatment executed (5). The gold standard for treatment for MPTT is a wide local excision with a 1-cm margin of normal tissue, although some Authors have been used chemotherapy and radiotherapy to prevent recurrence (11). We present a case of an unusual site of occurrence of MPTT with review of the literature.

## MATERIALS AND METHODS

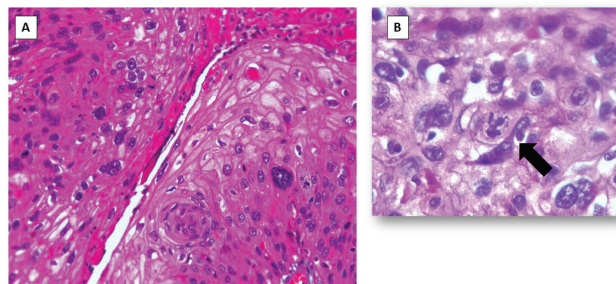
Our literature review was performed using the search medical databases PubMed, Scopus, Web of Science, and Google Scholar. Searches were performed using key terms "trichilemmal malignant", "trichilemmal malignant tumor", "trichilemmal malignant", "trichilemmal malignant tumor" and "malignant proliferating trichilemmal tumor", "proliferating trichilemmal carcinoma".

## CASE REPORT

A 51-year-old man presented with a gradually increasing, painless nodular swelling over scrotum, since several months, which ulcerated with bloody discharge. There was no history of trauma or skin cancers in the past. On examination, there was a 1.5 × 2 cm fungating growth over the scrotal region. There was no evidence of regional lymph node enlargement, even at US analysis. An excisional biopsy was done and the diagnosis of MPTT was given. A wider local excision of the scar was performed later. Histopathological examination of the biopsy was performed as previously described (12, 13) and showed a skin covered irregular lobulated mass measuring 2 cm in maximum diameter with just focal surface ulceration (**figure 1**). Microscopically, the dermis showed a cellular tumor composed of lobules and sheets of squamous cells with abrupt keratinization (**figure 1**). The cells were highly pleomorphic with hyperchromatic nuclei and high mitotic activity with abnormal mitotic figure as shown in (**figure 2**). Multinucleated tumor giant cells and foci of invasion into surrounding tissue were evident. The diagnosis of MPTT was made. The resected margins were free of tumor. The histopathological examination of the wider local excision specimen showed a sclerotic scar without residual images referable to MPTT. After 6 months of follow-up there are no signs of local recurrence or disease progression.



**Figure 1.** **A.** Mobile, polypoid and ulcerated mass in the left region of the scrotum; **B.** Histologically the neoplasm shows a dermic localization, with a lobulated architecture and abrupt keratinization (4x magnification, H&E staining).



**Figure 2.** **A.** High power magnification of MPTT. Atypical squamous cells with trichilemmal differentiation and evident nuclear pleomorphism; **B.** In a background of atypical squamous cells, atypical mitosis (black arrow) can be seen. (40x magnification, H&E staining).

## DISCUSSION

Proliferating trichilemmal tumors (PTTs) were originally described by Jones in 1966 as benign but locally aggressive skin neoplasms arising from the outer root sheath of hair follicles (14). MPTTs constitute less than 0.1% of skin cancers (15). The tumor usually appears on the scalp (>90% of cases), mostly affects women, occurring between the fourth and the eighth decade of life (16). Other rare site reported are the breast (17) arm (18), neck (19) jaw (20) sinuses (21) lip (22) eyelid (23) groin (24) orbit (25) and ear (26). Up to our knowledge this is the first case reported on the scrotum. The aetiology of this neoplasm is unknown, still, many of them originate from a pre-existing trichilemmal cyst (27). The progression of the tumor is slow but locally invasive. Ulcers may appear over time (28) as our case demonstrated. Histologic features of a MPTT that differentiate it from a benign TC or PTT include abnormal mitoses, high mitotic rate, marked cellular pleomorphism, architectural atypia, infiltrating margins, necrosis, and aneuploidy (8). The histopathological main differential diagnosis includes

ruptured trichilemmal cyst, giant trichilemmal horn and squamous cell carcinoma (SCC). Ruptured trichilemmal cysts may show irregular aggregates of keratinocytes with trichilemmal keratinization, but they should lack the solid multilobular structure and the cytological atypia. Giant cutaneous trichilemmal horns consist of a mixture of squamous epithelial cells and trichilemmal keratinized debris, mitoses can be common but not in the atypical form (29). PTTs are often confused histologically with metastatic or invasive SCC, as both can display keratinocytic nuclear atypia and infiltrative growth (30). On pathology, MPTTs are distinguished from SCC by trichilemmal keratinization involving an abrupt transition of nucleated to anucleated keratinized epithelium without granular layer. Sometimes can be found even invasive growth extending beyond the confines of the cyst wall, with irregular border, that make the differential diagnosis quite challenging (31). Immunohistochemical stains may be helpful tool. Herrero *et al.* reported that in the diagnosis of MPTT, cellular aneuploidy and CD34 loss are important markers (32). Moreover, p53 and Ki-67 markers in immunohistochemical examination are guiding in predicting the aggressiveness of the tumor (low grade-high grade). Decreased expression of p53, which is responsible for the repair of DNA damage, and increased expression of Ki-67, which indicates a high rate of mitosis in the cell, have been associated with malignant transformation and high recurrence rates (33-35). In a review of the literature, 93 well-documented cases of MPTTs were found, beyond our case (36-41). Furthermore, differential diagnosis between MPTTs and other skin cancer with squamous differentiation, including both squamous cell carcinoma and adnexal neoplasms with squamous differentiation can be challenging (42). We report a series of twenty-five MPTT (**table I**), using the search medical databases PubMed, Scopus, Web of Science, and Google Scholar Searches. The majority of cases occurred in female patients (15/25, 60%) and in the head and neck area (21/25, 84%), especially on the scalp (12/21, 57%). Radical surgical excision of neoplasm, with free-margins, was often curative, with no disease recurrence (15/21, 71.4%), and metastatic or relapsing disease was infrequently observed (6/21,

28%), with two (2/21.9%) cases of death for disease. In our knowledge this is the first case of MPTT arising on scrotum. MPTT was treated with surgical excision and resected margins were free of tumor. The outcome is satisfying, and the six-month follow-up showed no recurrence of disease. A guideline with a high level of evidence could not be established for their treatment since MPTTs are seen very rarely. According to most published paper surgery is favoured as gold standard, and the exact approach should be based on clinical judgment (35). Usually, surgical excision with a margin of 1 cm is the main step in the treatment of almost all MPTTs. Ye *et al.* (36) examined 76 proliferating trichilemmal tumors (PTT) in order to outline histopathologic features that could predict clinical behaviour and prognosis. Three distinct PTT variants were described based on malignant features such as nuclear atypical, mitotic activity, and presence of necrosis. Group I lesions are considered benign with recurrence not observed. Histopathologic examination reveals trichilemmal keratinization, focal nuclear atypia, mononuclear infiltrates, and absence of mitotic figures, perineural invasion, or vascular invasion. Group II lesions are low-grade malignant tumors with an increased risk of local recurrence. Histologically, these tumors are noted to have abrupt keratinization, areas of single-cell necrosis, and desmoplastic stroma. Cytologic atypia is absent. Group III lesions are high-grade malignant tumors with a high risk of recurrence, lymph node involvement, and/or distant metastasis. The case presented displayed histological features corresponding to group II lesion. Fortunately, our patient underwent surgery in the initial phase of the disease, therefore at the follow-up six months after the enlargement of the previous excision, there were no signs of disease, and no further therapy was necessary. Radiotherapy and chemotherapy have been used as adjuvant therapy in aggressive cases or recurrence (16). Patients should be followed closely and examined often to frequently assess recurrence or metastasis. Lymph node examination, US, CT, and in selected cases PET scan are recommended for pre-treatment staging. It is difficult to make accurate predictions about the clinical course since most of the MPTT cases in the literature have been reported as small case series.

## CONCLUSIONS

MPTTs are rare adnexal tumors that require a multidisciplinary approach to diagnosis and treatment. Sometimes the morphological features are

not easy to correlate with its clinical presentation, and diagnosis can be tricky, especially in unusual site. To create treatment algorithms, there is a need for increased case reports and comparative long-term results of different treatment options.

**Table I.** Review of twenty-five MPTTs.

N. CASES	AGE	SEX	SITE	ONSET	TREATMENT	OUTCOME	REFERENCE
1	Unknown	Unknown	Unknown	PTT with malignant transformation	SE	Unknown	<i>Markal et al. (1)</i>
2	66 Yr	Male	Scalp	De novo	SE	MD	<i>Ye et al. (36)</i>
	66 Yr	Female	Forehead	De novo	SE	MD	
1	63 Yr	Male	Scalp	De novo	SE	NR	<i>Tikku et al. (30)</i>
1	58 Yr	Female	Scalp	PTT with malignant transformation	SE	MD and DFD	<i>Mori et al. (37)</i>
3	64 Yr	Female	Scalp	De novo	SE	NR	<i>Herrero et al. (32)</i>
	53 Yr	Male	Scalp	De novo	SE	NR	
	66 Yr	Female	Scalp	De novo	SE	LTF	
1	52 Yr	Female	Scalp	De novo	SE	NR	<i>Alici et al.</i>
1	97 Yr	Female	Scalp	PTT with malignant transformation	SE	NR	<i>Fernando et al. (8)</i>
1	86 Yr	Male	Jaw	De novo	SE	Unknown	<i>Fernandez (18)</i>
1	58 Yr	Female	Scalp	NA	CT and RT	NR	<i>Casas et al. (9)</i>
1	65 Yr	Female	Scalp	De novo	SE	NR	<i>Gulati et al. (39)</i>
1	62 Yr	Female	Breast	De novo	SE	NR	<i>Akrami et al. (40)</i>
1	67 Yr	Female	Breast-Axilla	De novo	SE	NR	<i>Uchida et al. (15)</i>
1	63 Yr	Male	Arm-Wrist-Hand	De novo	SE	NR	<i>Aneiros-Fernandez et al. (16)</i>
1	32 Yr	Male	Neck	De novo	SE	LTF	<i>Durairaj et al. (17)</i>
1	56 Yr	Female	Jaw	NA	SE and CT	MD and DFD	<i>Hayashi et al. (41)</i>
1	53 Yr	Male	Sinuses	De novo	SE	ROD	<i>Harris et al. (21)</i>
1	75 Yr	Male	Lip	PTT with malignant transformation	SE	NR	<i>Kim HJ et al. (22)</i>
1	42 Yr	Female	Eyelid	De novo	SE	NR	<i>Lee et al. (23)</i>
1	80 Yr	Female	Orbit	De novo	Recommended RT	MD	<i>Ogul et al. (25)</i>
1	79 Yr	Male	Ear	PTT with malignant transformation	SE	NR	<i>Vandeweyer et al. (26)</i>
2	69 Yr	Female	Scalp	De novo	SE and RT	NR	<i>Cavanagh et al. (5)</i>
	53 Yr	Female	Scalp	De novo	SE	NR	

Yr: years; MD: metastatic disease (lymph node and/or distant metastasis); SE: Surgical excision; NR: no recurrence; DOD: died for disease; LTF:lost to follow-up; CT: Chemotherapy; RT: radiotherapy; ROD: recurrence of disease; NA: not available.

## COMPLIANCE WITH ETHICAL STANDARDS

### Fundings

There were no institutional or private fundings for this article.

### Conflict of interests

The Authors have declared no conflict of interests.

### Availability of data and materials

All data generated or analyzed during this study are included in this published article.

### Authors' contributions

All the Authors listed in the manuscript contributed substantially to the conception and design of the work, or to the acquisition, analysis or interpretation of data for the work. All Authors drafted the work or reviewed it critically. All Authors have given final approval of the version to be published. All Authors agree to be responsible for all aspects of the work ensuring that issues relating to the accuracy or integrity of any part of the work are properly investigated and resolved.

### Ethical approval

#### *Human studies and subjects*

The written informed consent was obtained from the patient before enrolment in the study to permit the use of the data generated in retrospective analyses.

#### *Animal studies*

N/A.

### Publication ethics

#### *Plagiarism*

The contents of the article are original and any overlaps with other articles are by the Authors themselves and appropriately cited.

#### *Data falsification and fabrication*

N/A.

## REFERENCES

1. Markal N, Kurtay A, Velidedeoğlu H, Hücümenoğlu S. Malignant transformation of a giant proliferating trichilemmal tumor of the scalp: patient report and literature review. *Ann Plast Surg.* 1998;41(3):314-6. doi: 10.1097/00000637-199809000-00017.
2. Saida T, Oohara K, Hori Y, Tsuchiya S. Development of a malignant proliferating trichilemmal cyst in a patient with multiple trichilemmal cysts. *Dermatologica.* 1983;166:2038. doi: 10.1159/000249868.
3. Folpe AL, Reisenauer AK, Mentzel T, Rütten A, Solomon AR. Proliferating trichilemmal tumors: Clinicopathologic evaluation is a guide to biologic behavior. *J Cutan Pathol.* 2003;30:492-8. doi: 10.1034/j.1600-0560.2003.00041.x.
4. Goyal S, Jain BB, Jana S, Bhattacharya SK. Malignant proliferating trichilemmal tumor. *Indian J Dermatol.* 2012;57(1):50-2. doi: 10.4103/0019-5154.92679.
5. Cavanagh G, Negbenebor NA, Robinson-Bostom L, Walker JL. Two Cases of Malignant Proliferating Trichilemmal Tumor (MPTT) and Review of Literature. *R I Med J* 2022;105(1):12-16. Available from: <http://rimed.org/rimedical-journal/2022/02/2022-02-12-case-cavanaugh.pdf>. Accessed: Oct 21, 2022.
6. Janitz J, Wiedersberg H. Trichilemmal pilar tumors. *Cancer.* 1980;45:1594-7. doi: 10.1002/1097-0142(19800401)45:7<1594::aid-cn-cr2820450713>3.0.co;2-o. [https://acsjournals.onlinelibrary.wiley.com/doi/10.1002/1097-0142\(19800401\)45:7%3C1594::AID-CN-CR2820450713%3E3.0.CO;2-O](https://acsjournals.onlinelibrary.wiley.com/doi/10.1002/1097-0142(19800401)45:7%3C1594::AID-CN-CR2820450713%3E3.0.CO;2-O)
7. Kim UG, Kook DB, Kim TH, Kim CH. Trichilemmal Carcinoma from Proliferating Trichilemmal Cyst on the Posterior Neck. *Arch Craniofac Surg.* 2017;18(1):50-3. doi: 10.7181/acfs.2017.18.1.50.
8. López-Ríos F, Rodríguez-Peralto JL, Aguilar A, Hernández L, Gallego M. Proliferating trichilemmal cyst with focal invasion: report of a case and a review of the literature. *Am J Dermatopathol.* 2000;22(2):183-7. doi: 10.1097/00000372-200004000-00018.
9. Casas JG, Woscoff A. Giant pilar tumor of the scalp. *Arch Dermatol.* 1980;116(12):1395. Available from: <https://jamanetwork.com/journals/jamadermatology/article-abstract/541608>. Accessed: Oct 21, 2022.
10. Weiss J, Heine M, Grimm M, Jung EG. Malignant proliferating trichilemmal cyst. *J Am Acad Dermatol.* 1995;32:870-3. doi: 10.1016/0190-9622(95)91550-8.
11. Satyaprakash AK, Sheehan DJ, Sanguenza OP. Proliferating trichilemmal tumors: a review of



- literature. *Dermatol Surg.* 2007;33:1102-8. doi: 10.1111/j.1524-4725.2007.33225.x.
12. Spugnini EP, Menicagli F, Giacomella R, Zanni F, Camponi C, De Luca A, et al. Filling the gap between histology and cytology: description of an innovative technology (Cytomatrix) to increase the diagnostic effectiveness of fine needle aspirates data. *J Clin Pathol.* 2021;74(4):269-70. doi: 10.1136/jclinpath-2020-206545.
  13. Bonucci M, Minelli S, Lo Castro C, Camponi C, Scimeca M, Scipioni A, et al. Cytomatrix, a new procedure to enhance the diagnostic usefulness of fine needle aspirates. *Ann Oncol Res.* 2021;1(13):143-9. doi: 10.48286/aro.2021.33.
  14. Jones EW. Proliferating epidermoid cysts. *Arch Dermatol.* 1966;94(1):11-9. doi: 10.1001/archderm.1966.01600250017002.
  15. Siddha M, Budrukkar A, Shet T, Deshpande M, Basu A, Patil N, et al. Malignant pilar tumor of the scalp: a case report and review of literature. *J Cancer Res Ther.* 2007;3(4):240-3. doi: 10.4103/0973-1482.39001.
  16. Kemaloglu CA, Öztürk M, Aydın B, Canöz Ö, Eğilmez O. Malignant proliferating trichilemmal tumor of the scalp: report of 4 cases and a short review of the literature. *Case Reports Plast Surg Hand Surg.* 2022;9(1):158-64. doi: 10.1080/23320885.2022.2077208.
  17. Uchida N, Tsuzuki Y, Ando T, Mochida Y, Yoshikawa M, Sekihara M, et al. Malignant proliferating trichilemmal tumor in the skin over the breast: a case report. *Breast Cancer.* 2000;7(1):79-82. doi: 10.1007/BF02967193.
  18. Aneiros-Fernandez J, Jimenez-Rodriguez JM, Martin A, Arias-Santiago S, Concha A. Giant proliferating trichilemmal malignant tumor. *Indian J Dermatol Venereol Leprol.* 2011;77(6):730. doi: 10.4103/0378-6323.86507.
  19. Durairaj AR, Mahipathy SR, Vivakaran TT, Harikrishnan V, Esakki M. Malignant Proliferative Trichilemmal Tumor of The Nape of The Neck - A Case Report. *J Clin Diagn Res.* 2016;10(2):PD19-20. doi: 10.7860/JCDR/2016/17167.7258.
  20. Fernandez SH. Malignant proliferating trichilemmal tumour: a case report. *Malays J Pathol.* 1999;21(2):117-21. Available from: <https://pubmed.ncbi.nlm.nih.gov/11068417/>. Accessed: Oct 21, 2022.
  21. Harris T, Meyer E, Lubbe DE, Smit W, Walker C. Malignant proliferating trichilemmal tumor involving the sinuses. *Ear Nose Throat J.* 2011;90(7):E5-8. doi: 10.1080/23320885.2022.2077208.
  22. Kim HJ, Kim TS, Lee KH, Kim YM, Suh CH. Proliferating trichilemmal tumors: CT and MR imaging findings in two cases, one with malignant transformation. *AJNR Am J Neuroradiol.* 2001;22(1):180-3.
  23. Lee SJ, Choi KH, Han JH, Kim YD. Malignant proliferating trichilemmal tumor of the lower eyelid. *Ophthalmic Plast Reconstr Surg.* 2005;21(5):349-52. doi: 10.1097/01.iop.0000167787.91245.f6.
  24. Noto G, Pravatà G, Aricó M. "Shadow" cells in proliferating trichilemmal tumors. *Am J Dermatopathol.* 1990;12(3):319-20.
  25. Ogul H, Keles S, Yildirim K, Bassorgun CI, Eren S, Kantarci M. Orbital malign trichilemmal tumor with cerebral involvement. *J Craniofac Surg.* 2014;25(1):e21-23. doi: 10.1097/SCS.0b013e-3182a2ed5a.
  26. Vandeweyer E, Renard N, Shita-Hayez F. Proliferating trichilemmal cyst with malignant transformation. *Eur J Plast Surg.* 2004;27:33-36.
  27. Poiars Baptista A, Garcia E Silva L, Born MC. Proliferating trichilemmal cyst. *J Cutan Pathol.* 1983;10(3):178-87. doi: 10.1111/j.1600-0560.1983.tb00324.x.
  28. Shet T, Modi C. Nucleolar organizer regions (NORs) in simple and proliferating trichilemmal cysts (pilar cysts and pilar tumors). *Indian J Pathol Microbiol.* 2004;47(4):469-73.
  29. Michal M, Bisceglia M, Di Mattia A, Requena L, Fanburg-Smith JC, Mukensnabl P, et al. Gigantic cutaneous horns of the scalp: lesions with a gross similarity to the horns of animals: a report of four cases. *Am J Surg Pathol.* 2002;26(6):789-94. doi: 10.1097/00000478-200206000-00014.
  30. Tikku G, Jain D, Grover R. Malignant proliferating trichilemmal tumor of the scalp masquerading as squamous cell carcinoma: a need for common awareness. *Indian J Pathol Microbiol.* 2014;57(4):646-7. doi: 10.4103/0377-4929.142705.
  31. Agarwal C, Pujani M, Raychaudhuri S, Arora S, Rana D, Chauhan V. Squamous Cell Carcinoma versus Malignant Proliferating Trichilemmal Tumor: A Histopathological Dilemma with Review of Literature. *Indian J Dermatol.* 2019;64(4):339. doi: 10.4103/ijd.IJD\_229\_17.
  32. Herrero J, Monteagudo C, Ruiz A, Llobart-Bosch A. Malignant proliferating trichilemmal tumor s: an histopathological and immunohistochemical study of three cases with DNA ploidy and morphometric evaluation. *Histopathology.* 1998;33(6):542-6. doi: /10.1046/j.1365-2559.1998.00549.x

33. Rangel-Gamboa L, Reyes-Castro M, Dominguez-Cherit J, Vega-Memije E. Proliferating trichilemmal cyst: the value of ki67 immunostaining. *Int J Trichology*. 2013;5(3):115-7. doi: 10.4103/0974-7753.125599.
34. Khodaeiani E, Fakhrjou A, Amirnia M, Babaei-Nezhad S, Taghvamanesh F, Razzagh-Karimi E, et al. Immunohistochemical evaluation of p53 and Ki67 expression in skin epithelial tumors. *Indian J Dermatol*. 2013;58(3):181-7. doi: 10.4103/0019-5154.110824.
35. Osto M, Parry N, Rehman R, Ahmed U, Mehregan D. Malignant Proliferating Trichilemmal Tumor of the Scalp: A Systematic Review. *Am J Dermatopathol*. 2021;43(12):851-66. doi: 10.1097/DAD.0000000000001991.
36. Ye J, Nappi O, Swanson PE, Patterson JW, Wick MR. Proliferating pilar tumors: a clinicopathologic study of 76 cases with a proposal for definition of benign and malignant variants. *Am J Clin Pathol*. 2004;122(4):566-74. doi: 10.1309/OXLEGFQ64XYJU4G6.
37. Mori O, Hachisuka H, Sasai Y. Proliferating trichilemmal cyst with spindle cell carcinoma. *Am J Dermatopathol*. 1990;12(5):479-84. doi: 10.1309/OXLEGFQ64XYJU4G6.
38. Alici O, Keles MK, Kurt A. A Rare Cutaneous Adnexal Tumor: Malignant Proliferating Trichilemmal Tumor. *Case Rep Med*. 2015;2015:742920. doi: 10.1155/2015/742920.
39. Gulati HK, Deshmukh SD, Anand M, Morale V, Pande DP, Jadhav SE. Low-grade malignant proliferating pilar tumor simulating a squamous-cell carcinoma in an elderly female: a case report and immunohistochemical study. *Int J Trichology*. 2011;3(2):98-101. doi: 10.4103/0974-7753.90818.
40. Akrami M, Talei A, Nazemzadegan B, Abdollahi A, Aslani FS, Safaei A, et al. Low grade malignant proliferating pilar tumor arising from breast skin simulating squamous cell carcinoma, a case report. *Indian J Surg Oncol*. 2013;4(4):397-8. doi: 10.1007/s13193-013-0275-2.
41. Hayashi I, Harada T, Muraoka M, Ishii M. Malignant proliferating trichilemmal tumor and CAV (cisplatin, adriamycin, vindesine) treatment. *Br J Dermatol*. 2004;150(1):156-7. doi: 10.1111/j.1365-2133.2004.05670.x
42. Pagliuca F, Ronchi A, Briatico G, Schiano E, Fiorentino F, Argenziano G, Franco R. Massive squamous differentiation and anaplastic features in eccrine porocarcinoma as rare and confounding elements. *Australas J Dermatol*. 2021;62(2):e320-e321. doi: 10.1111/ajd.13472.